



**American Journal of
Medicine and
Medical Sciences**

Periodontal Diseases and Morphological Changes in Employees with Varying Seniority in the Manufacturing Industry

Ravshan Usmanov¹, Azamat Nortae², Nilufar Nortae³, Gulnara Islamova⁴,
Makhmuda Sakdullaeva⁵, Aliyor Normuradov², Shakhzoda Ibrakhimova²

¹Doctor of Medical Sciences, Professor of the Department of Human Anatomy and OSTA of the Tashkent Medical Academy, Uzbekistan

²Assistant of the Department of Human Anatomy and OSTA, Tashkent Medical Academy, Uzbekistan

³PhD, Senior Teacher of the Department of Human Anatomy and OSTA, Tashkent Medical Academy, Uzbekistan

⁴Dosent of the Department of Human Anatomy and OSTA, Tashkent Medical Academy, Uzbekistan

⁵Senior Teacher of the Department of Human Anatomy and OSTA, Tashkent Medical Academy, Uzbekistan

Abstract This study investigated the impact of air pollution caused by textile combine dyeing and finishing enterprises, specifically the emission of aerosolized paint particles. These aerosols significantly contribute to air contamination and pose health risks to workers. Prolonged exposure to these particles has been linked to various health issues, including tumor development. The aerosol droplets settle on the skin and penetrate the respiratory and digestive systems of workers, leading to adverse morphological changes, particularly in oral and periodontal tissues. The findings highlight that workshops involved in chemical dye production are major contributors to air pollution, dispersing a wide variety of harmful compounds into the environment. Measures to mitigate these occupational hazards are urgently needed to protect the health of employees.

Keywords Morphological changes, Teeth, Periodontal diseases, Employees, Men, Women, Chemical dyes

1. Introduction

In periodontal diseases, it has been suggested that tissue damage in one area can spread to other tissues, or alternatively, all affected tissues may become simultaneously infected, leading to the concept of considering them as a unified tissue complex [1,2,3,4,5,11,12]. In the manufacturing industry, particularly in the textile sector, various organic and inorganic dye solutions are extensively used in dyeing and finishing enterprises [6,7,8,9,10,13,14,15]. These chemical dyes and solutions are known to induce autoallergenic reactions by denaturing proteins on the mucous membranes of the skin and respiratory tract [16,17,18,19,20]. Clinical and experimental studies conducted by several researchers among workers in manufacturing enterprises utilizing organic and inorganic compounds have comprehensively demonstrated the negative effects of chemical dyes, reagents, catalysts, and other substances on the tissues of the oral cavity and the entire body [21,22].

The purpose of the study. Study of parodont diseases and morphological changes in it in employees with different seniority working in the manufacturing industry.

2. Research Materials and Methods

Studies from 2021 to 2024, from the Workers of the “Crystal” textile combine, located on the territory of the Yangiyol District Medical Association of the Yangiyol District of the Tashkent region, we selected 575 employees. Of this, 416 (72.34%) are male employees and 159 (27.65%) are female employees. The minimum age for selected employees is 20 years, while the maximum age is 48 years or older. First of all, when studying a number of changes in the oral cavity in employees, parodont levels also paid special attention to the work process in which they actively perform.

Paint House department
Laboratory Department
Drying unit
Finished fabric section
Fabric coloring section

In addition, there are also sections such as bugalteria, cadres. Basically, we divided all the employees of the enterprise into two groups: Group 1, which is not in contact with chemical dyes (control), and group 2, which is in contact with chemical dyes (basic). In addition to periodontal disease in these employees, oral infections, tongue leukoplakia and various stomatitis are also common among them (Table 1).

Table 1. Information on the age and seniority of workers of the textile enterprise "Crystal"

General specification	Seniority groups (Year)	Total workers, number, 575 people	Men 416	Women 159
Workers average age	4	24,2±2,3	27	30
	7	28,4±7,22	29	35
	9	29,4±5,8	32	37
Youngest age degree	4	20	20	23
	7	20	29	27
	9	20	35	30
Highest age degree	4	58	33	37
	7	58	45	48
	9	58	58	52

3. Results

Studies have found that the percentage of periodontal disease in paint shop employees was higher in female employees than in male employees. In addition to periodontal disease, workers in paint shops also suffer from leukoplakia, stomatitis and various inflammations in the oral cavity. For example, periodontal disease was found from 165 employees (28.69%) with up to 4 years of seniority in sex (122 male employees and 43 female employees). They are between 27 and 30 years old and average 24.2±2.3 years. Periodontal disease was also observed in 268 employees (46.61%) with 7-year seniority (199 men and 69 women). Their age, on the other hand, was estimated to be between 29 and 35 years old and an average of 28.4±7.22 years. 142 employees (24.69%) with 9 years of work experience (95 male employees and 47 female employees) reported periodontal disease. In terms of age, however, it was between 32 and 37 years old and averaged 29.4±5.8 years (diagram 1). Alternatively, among employees in contact with chemical dyes (observation group), along with periodontal disease, we can see that oral infections, tongue leukoplakia and various stomatitis are also common, as well as the appearance of cracks in the teeth, bleeding gums, moving teeth and even discoloration of the teeth.

In the course of determining whether employees of the textile enterprise "Crystal" had periodont disease, we tried, first of all, not to undermine the work process of employees, not to undermine their performance. That is why we used the shortest methods that determine whether there is periodont disease and at what stage it is. In doing so, we did it in conjunction with the medical officer of the enterprise. In dentistry today, there are many methods that determine the index of oral hygiene and periodontitis (periodontitis). But it is precisely in the short term in the employees of the enterprise, with ready-made laboratory preparations to determine the degree of periodont disease, as well as at what stage:

- PI
- PMA

We used the methods.

We also found PI in each selected employee, calculated using the formula below.

$$PI = \text{evaluation of each tooth} / \text{number of teeth}$$

According to the resulting result, the degrees of parodont disease were determined, and they are as follows.

Table 2. PI-derived results (ball)

Employee seniority (years)	Employees of the compartment in the container with chemical dyes (control group)		Personnel on the contact with chemical dyes (main group)	
	Men	Women	Men	Women
4	0,06±0,068	0,08±0,187	3,0±0,156	2,2±0,133
7	0,031±0,173	0,45±0,251	3,95±0,16	3,11±0,179
9	0,19±0,225	1,13±0,114	3,02±0,153	4,0±0,162

Note: - p<0.05 is reliable compared to the control group

PI - induced results showed that in 71 employees who were not in contact with chemical dyes (control group), PI indicators recorded indicators below standard scores. This showed that they did not have a parodont. 504 employees in contact with chemical dyes (core group), however, were diagnosed with periodont disease and diagnosed with Pi disease levels.

Our observations corresponded to the information received from the medical card "primary dental examination card of employees", which is stored in the medical officer of the enterprise, and the outpatient Card (Form №. 043), which is kept by the nurse of the New District Medical Association, as well as the nurse of the dental Polyclinic. Observation revealed that the percentage of periodontal disease also increased as working hours increased. Among Periodontal diseases, gingivitis occurs mainly in people with less than 9 years of experience, while periodontitis occurs in workers with more than 9 years of experience.

Our observations corresponded to the information received from the medical card "primary dental examination card of employees", which is stored in the medical officer of the enterprise, and the outpatient Card (Form No. 043), which is kept by the nurse of the New District Medical Association, as well as the nurse of the dental Polyclinic. Observation revealed that the percentage of periodontal disease also increased as working hours increased. Among Periodontal diseases, gingivitis occurs mainly in people with less than 9 years of experience, while periodontitis occurs in workers with more than 9 years of experience. We continued to monitor employees who were diagnosed with periodontitis. We received employees who applied to the new District Medical Association and The New District Dental Polyclinic for histological examination of teeth tremors. And we studied it in the hemotoxilin-eosin and Van-gizone methods (Figure 1).

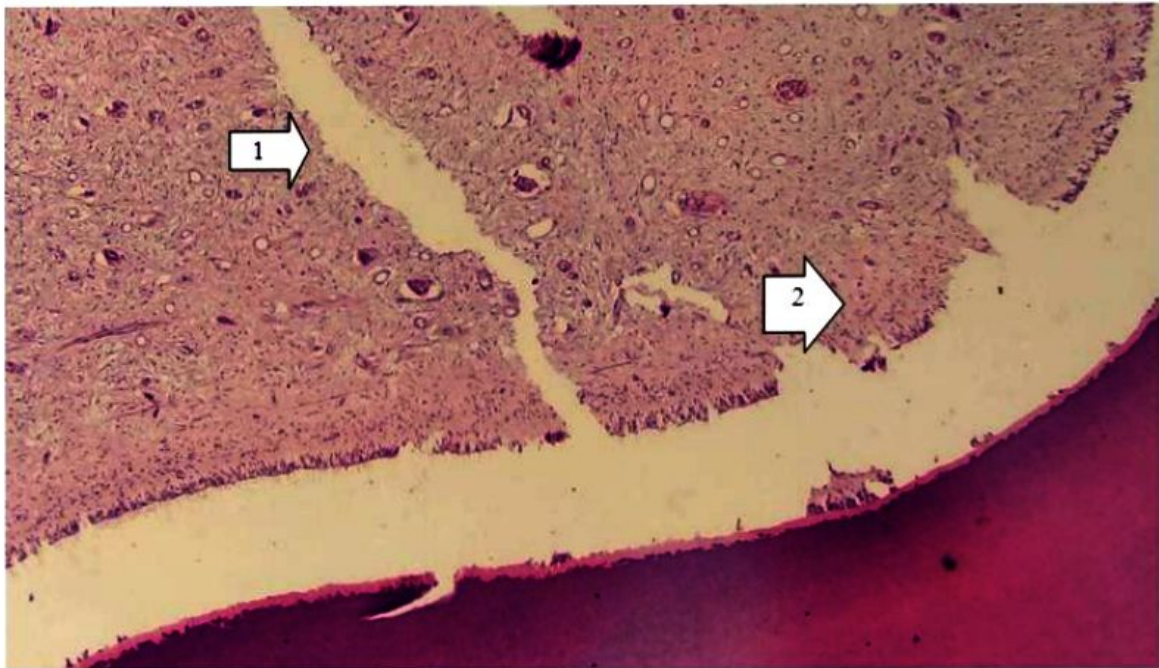


Figure 1. Parodont of the identified employee histological appearance of the tooth. Dentin channels (1) and Sharpey appearance of fibers (2). Staining: hematoxylin-eosin X:10x10

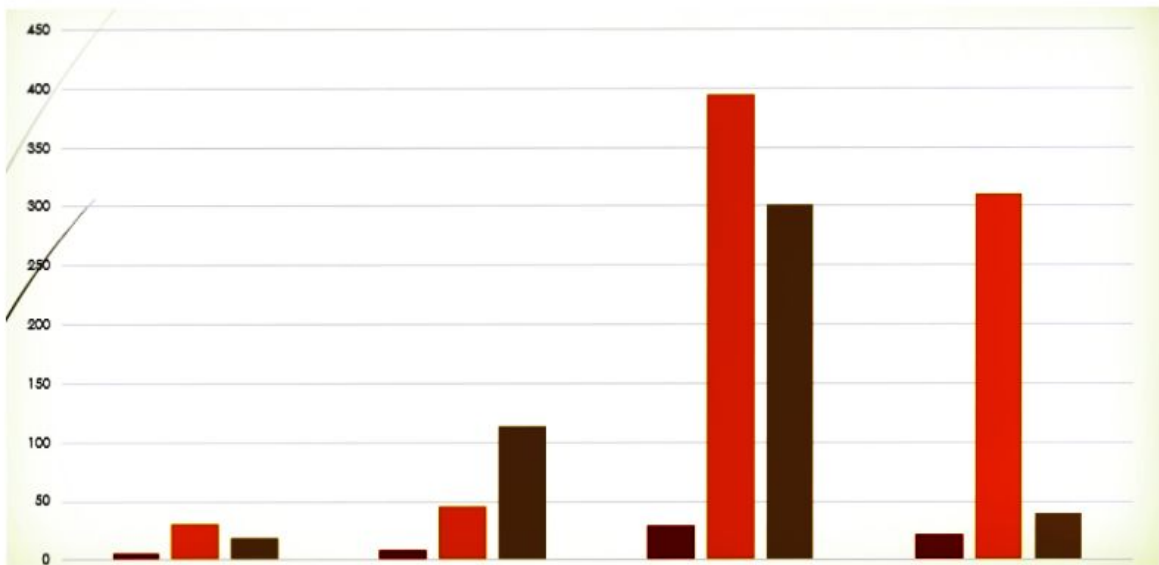


Figure 2. Subjective examination results in employees of a textile enterprise

In cement, it is illuminated that collagen fibers and cementocytes lie between non-cellular substances. Alternatively, it was observed that the Sharpey fibers were enlarged as well as that the tip of these fibers was adjacent to the radial fibers of the dentin. Complete vascular bleeding was also found in the pulp of the tooth as well as erythrocytes and diapedesis hemorrhages, as well as hemodynamic disturbances in the appearance of perivascular spaces in a swollen state.

Vacuoles containing tissue fluid were also found. Alternatively, connective tissue made up of nerve fibers has been identified. The cytoplasm of odontoblasts (dentinoblasts) was observed to be vacuolized and signs of hydropic dystrophy developed. It was noted that its cytoplasm is small granularity in size as well as basophilicity, and the nucleus is located in the basal

part of the cell.

In addition, the following inspections were carried out on the employees of the textile enterprise "crystal", that is, in a subjective inspection; tooth fissure formation is 16.2% in the control group, 36.11% in the main group, tooth decay is 39.15% in the control group, 51% in the main group, tooth acuity is 69% in the control group, 76.19% in the main group, tooth decay is 12.25% in the control group, 29.2% in the main group, tooth discoloration is 14.72% in the control group, 25.4% in the main group, 41.6% of cases (Figure 2) were recorded. The survey showed that there was a need to develop plans that relied on novel socio-economic conditions in organizing the dental service. It is also desirable to implement the shortest, fastest methods in determining the parodont.

4. Discussion

The findings of this study highlight the significant impact of occupational exposure to chemical dyes on the periodontal health of employees working in textile combine dyeing and finishing enterprises. The results demonstrate that employees in contact with chemical dyes exhibit a higher prevalence of periodontal diseases, as well as associated complications such as leukoplakia, stomatitis, and other oral infections, compared to those not exposed.

Prolonged exposure to aerosolized paint particles and chemical dyes leads to adverse health outcomes. These aerosols act as autoallergenic agents, denaturing proteins on the mucous membranes of the skin and respiratory tract, which significantly contributes to the development of inflammatory conditions in the oral cavity. The correlation between the duration of exposure and the severity of periodontal disease was evident, with longer exposure periods resulting in more advanced stages of periodontitis.

The study found a higher prevalence of periodontal disease among female employees compared to males, despite similar exposure conditions. This discrepancy may be attributed to physiological and hormonal differences, as well as potential disparities in immune response and oral hygiene practices.

Histological analysis of affected tissues revealed significant pathological changes, including vacuolization of odontoblast cytoplasm, hydropic dystrophy, and enlargement of Sharpey fibers. These findings suggest that chemical exposure not only induces inflammatory responses but also disrupts the structural integrity of periodontal and dental tissues.

The study highlights the necessity for improved occupational safety measures in dyeing and finishing enterprises. Regular health screenings, particularly focusing on oral health, are essential for early detection and management of periodontal diseases. Additionally, implementing workplace modifications to reduce aerosol dispersion, such as improved ventilation systems and personal protective equipment, could mitigate health risks.

Further studies are needed to explore the long-term effects of occupational exposure on systemic health and to develop targeted interventions for at-risk populations. Investigating the potential role of nutritional and lifestyle factors in mitigating these adverse outcomes could also provide valuable insights.

This research provides compelling evidence of the detrimental effects of chemical dyes on the periodontal health of textile workers. Comprehensive health programs and stricter regulatory measures are necessary to protect employees from the occupational hazards associated with chemical dye exposure. By addressing these risks, workplaces can improve the overall well-being and productivity of their workforce.

5. Conclusions

1. In addition to periodontal disease, paint shop workers also suffer from leukoplakia, stomatitis and various inflammations in the oral cavity.

2. As a result of our observations, it turned out that in a certain percentage of employees there, depending on seniority, periodontal disease, its development, complications arose, that is, inflammation of the gums, swelling, fragility of teeth were also found.
3. Alternatively, among employees in contact with chemical dyes (observation group), along with periodontal disease, we can see that oral infections, tongue leukoplakia and various stomatitis are also common, as well as the appearance of cracks in the teeth, bleeding gums, moving teeth and even discoloration of the teeth.

REFERENCES

- [1] Akhmedova S.M., Nortaeva N.A., Nortaev A.B. Morphological changes in the teeth of adolescent children with hypotireosis // Collection of materials of the scientific and practical conference with international participation, dedicated to the 100th anniversary of the Tashkent Medical Academy, "100 years of the Tashkent Medical Academy – the era of great achievements and discoveries". Tashkent, 2022 -P. 199-200.
- [2] Nortaeva N.A., Akhmedova S.M., Nortaev A.B. Morphological changes in the teeth adolescent children with hypotireosis // Problems of biology and medicine. - Samarkhand, 2022. - P 270. ISSN 2182-5674, <https://doi.org/10.38096/2181-5674>. 2022.
- [3] Nortaeva N.A., Nortaev A.B. Morphological changes in teeth against the background of experimental hypothyroidism // Topical issues of modern scientific research.-Dushanbe 2022. -P 168.
- [4] Nortaeva N.A., Nortaev A.B. Morphological changes in the tooth in experimental hypothyroidism // Issues of innovative development of science, education and technology. - Andijan, 2022. -P 273-275.
- [5] Nortaeva N.A., Nortaev A.B., Akhmedova S.M. To study the morphological changes in the tooth against the background of experimental hypothyroidism // Current problems of microbiology. - Tashkent, 2022 -P. 148-152.
- [6] Nortaeva N.A. Morphological changes in teeth as a result of malnutrition in preschool children // Proceedings of the conference dedicated to the 95th anniversary of academician, morphologist, scientist Komiljon Zufarov. - Tashkent, 2021 -P. 34-36.
- [7] Nortaeva N.A., Akhmedova S.M. Morphological changes in the dental in experimental hypotireosis // Collection of materials of the scientific and practical conference of young scientists with international participation, dedicated to the 100 th anniversary of the Tashkent Medical Academy, «innovative approaches in medicine». Tashkent, 2022 -P. 51.
- [8] Nortaeva N.A., Akhmedova S.M., Nortaev A.B. Anthropometric indicators of the maxillofacial system in school-aged children with hypothyroidism // Modern scientific research topical issues, achievements and innovations. Current scientific issues, current affairs, achievements and innovations. Penza, 2023 -P. 153. ISBN 978-5-00173-707-0.

- [9] Nortaeva N.A., Akhmedova S. M., Nortaev A.B., Rajabov B.M. Changes in the face-jaw system of experimental hypothyroidism // *Texas Journal of Medical Science* <https://zienjournals.com> 2023 –P. 61-64 ISSN NO: 2770-2936.
- [10] Nortaeva N., Akhmedova S., Berdiev O., Anthropometric dimensions of the maxillofacial system in children with hypothyroidism aged 8-16 year // *Journal of Medicine and Innovations* www.tsdj.uz 2023 –P. 230-235 ISSN 2181-1873.
- [11] Nortaeva N.A., Akhmedova S.M., Nortaev A.B, Effects of hypothyroidism on the maxillofacial system // *Uzbek journal of case reports* 2023 – P. 126, Том 3. <https://doi.org/10.55620/ujcr.3.sp.2023>.
- [12] Usmanov R.Dj., Gulmanov I.D., Nortaev A.B. Development and prevalence of periodontal diseases in workers working with chemical paints // 100 years of the Tashkent Medical Academy – the era of great achievements and discoveries – 2022. P-244.
- [13] Saidov A.A. Periodontal disease and its prevention in workers of the textile industry // *Monograph-2020*. 134 p.
- [14] Volozhin A.I., Filatova E.S., Petrovich Y.A. and others. Evaluation of the state of the periodontal by the chemical composition of the environment of the oral cavity // *Dentistry*. -2000. №1- P. 13-16.
- [15] Nortaev A.B., Rajabov B.M., Berdiev O.V. Oral inflammation in light industry workers // *Texas Journal of Medical Science* ISSN NO: 2770-2936. - 2023. P-84-86. <https://zienjournals.com>.
- [16] Nortaev A.B., Usmanov R.Dj., Nortaeva N.A. Periodontal disease and its complications in 21-30-year-old chemical paint workers // *Journal of medicine and innovations* ISSN 2181-1873 2023. P-215-220 www.tsdj.uz.
- [17] Nortaev A.B., Usmanov R.Dj., Berdiev O.V. Use of cefixime in the treatment of periodontal disease in industrial employees // *Farmaecutitl journal* №3, 2023 P. 77-80 UDK: 616.314.18-002.4-885:615.331:323.329.
- [18] Nortaev A.B., Usmanov R.Dj., Ibragimova Sh.A. Severe Consequences of the Development of Periodontal Disease in the Example of Employees Working in Light Industrial Plants // *Texas Journal of Medical Science* ISSN NO: 2770-2936 <https://zienjournals.com> Date of Publication: 06-05-2023 P-110-113.
- [19] Nortaev A.B., Usmanov R.Dj., Berdiev O.V. Periodontal disease and its complications in 21-30-year-old chemical paint workers // *Journal of oral medicine and craniofacial research* Samarkhand - 2023. P. -21.
- [20] Nortaev A.B., Akhmedova S.M., Usmonov R.Dj. Periodontal disease and its development in the case of employees of chemical shops // *Uzbek journal of case reports* Part 3. Samarkhand - 2023. P. -130.
- [21] Nortaev A.B., Usmanov R.Dj., Rajabov B.M. The level of periodontal disease in 20-28-year-old textile industry workers // 77th International Scientific and Practical Conference "Achievements of Fundamental, Applied Medicine and Pharmacy". Samarkhand - 2023. P. -525.
- [22] Nortaev A.B., Usmanov R.Dj., Gulmanov I. Dj. Etiology of the development of periodontal disease in workers of the manufacturing industry // "Current aspects of the pathogenesis of diseases caused by environmental factors" Materials of international scientific and practical conference Tashkent – 2023. P-11-12.