



UDK: 616-441.008.63-002:06]-092.9

**METHODS OF USING THE DRUG MERCAZOLIL IN  
EXPERIMENTAL HYPOTHYROIDISM**

*Nortayev Azamat Begmatovich,  
Islamova Gulnora Raufovna,  
Ibragimova Shakhzoda Abduraximovna,  
Inatov Akhmad Azamovich*  
Tashkent State Medical University,  
[azamatnortayev64@gmail.com](mailto:azamatnortayev64@gmail.com)

*The article provides information about the experimental hypothyroidism model with Mercazolil drug, the morphological and morphometric changes in the teeth that occur in Mercazolil-induced hypothyroidism. Against the background of experimental hypothyroidism caused by Mercazolil, changes such as expansion of the pulp, thinning of cement, and reduction of dentine were observed in the teeth.*

*Key words: mercazolyl, thyroxine, hypothyroidism, dentin, experimental groups, mechanism of action of the drug, hormones.*

Among the somatic diseases that are widespread among the population in the world, the frequency of thyroid gland diseases occupies a high place [7,8]. In our country, special attention is paid to the improvement of the medical field, including the improvement of the quality of diagnosis, treatment and prevention of various somatic diseases [1,2,9,10]. As a result of the increase in the amount of T3 and T4 hormones in the blood, the production of thyrotropin hormone of the pituitary gland decreases [4,5,11,12]. A decrease in the amount of the above hormones in the blood, on the contrary, causes an increase in the production of thyrotropin hormone [3,2,6].

**The purpose of the study:** Background of mercazolyl-induced experimental hypothyroidism and its study in white laboratory rats.



**Research materials and methods:** The teeth of 57 rats in the early postnatal ontogeny period were taken as the object of the study. We divided white laboratory rats into 2 groups. In the experimental group, 28 white laboratory rats were given 0.5 mg of mercazolil per 100 g of body weight for 14 days to induce experimental hypothyroidism, and blood was taken from the tail vein on different days of the experiment and examined for hormones. After it was clear that the hypothyroidism model was induced, we administered 0.25 mg mercazolil (maintenance) per 100 g of body weight to rats for 1 month. Group 2 was a control group of 29 rats, and these rats were given 1.0 ml of 1% midori starch suspension by gavage. Rats were killed under anesthesia on days 3, 7, 14, 21, 30 and 60. The teeth of the rats were taken, histological preparations were prepared from them, and their morphological structure was studied.

In order to justify the induction of experimental hypothyroidism in rats, the amount of triiodothyronine (T3), unbound thyroxine (T4) and thyrotropin hormone (TTG) was determined in the blood of rats on different days of the experiment. The analysis of the obtained data showed that the experiment At the age of 7 days, the T3 and T4 hormones of the hypothyroid and control group rats are almost not different from each other. Day 14 of the experiment there was a clear decrease in T4 and a less pronounced decrease in T3. The indicator of the T4 hormone on the 21st day of the experiment 2 times, and T3 was found to decrease by 1 time. Thyroid hormones in the blood of 30-day-old rats changed according to T4 index 4 times, and T3 decreased by one and a half times. Thus, the analysis of the hormone indicator showed a reliable decrease in the indicator of thyroxine (T4) hormone in the blood of rats in the case of experimental hypothyroidism. The reduction of the T4 hormone was clearly reflected from day 14, and by the last 30 and 60 days of the experiment, the reliability decreased up to 4 times.

The amount of thyroid hormones in the blood is controlled by thyrotropin. A decrease in the amount of T3 and T4 hormones in the blood led to an increase in the TTG hormone.

On days 3 and 7, the amount of TTG is the same as in the control group. By the 14th day of the experiment, a gradual increase in TTG was noted, and by the 21st day, it was twice as high as in the control group.

Table 1.

**Hormone levels in the blood of rats in the control and experimental groups**

Days	Hormone levels in the blood (M ± m)					
	Control group			Experimental group		
	TTG (mkME / ml)	Triiodothyronine (T3)	Thyroxine (Unbound T4) (pmol / l)	TTG (mkME / ml)	Triiodothyronine (T3)	Thyroxine (Unbound T4) (pmol / l)
3 day	0,11±0,05	7,5±0,08	12,00±0,5	0,9±0,6	6,3±0,07	8,5±0,07
7 day	0,17±0,4	7,3±0,04	12,00±1,7	0,15±0,8	6,5±0,5	9,7±0,3
14 day	0,5±0,03	8,6±1,13	11,00±1,14	0,2±0,08	4,06±0,7	5,09±0,6
21 day	0,25±0,06	8,9±0,5	11,00±0,65	0,25±0,1 1	3,9±0,3	3,6±0,5
30 day	0,19±0,16	9,5±0,6	12,00±1,34	0,23±0,0 9	3,3±0,4	2,7±0,5
60 day	0,23±0,09	10,04±0,0 2	12,00±1,43	0,29±0,8	3,01±0,3	1,9±0,07

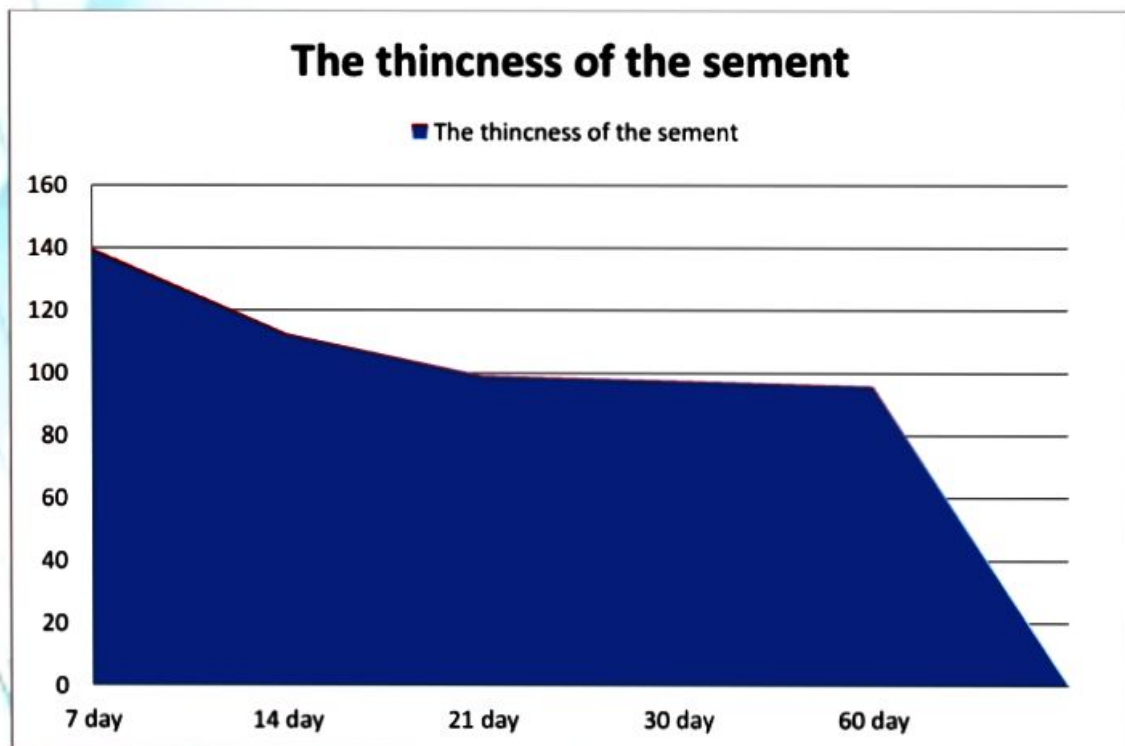
**Results of the study:** When the morphological structure of the teeth of rats in the control group was studied, the thickness of the enamel layer was  $3620.1 \pm 3.6 \mu\text{m}$ , the thickness of the dentin was  $684.2 \pm 27.6 \mu\text{m}$ , the thickness of the predentin was  $25.83 \pm 1.0 \mu\text{m}$ , and the pulp was  $926.8 \pm 37.4 \mu\text{m}$ . , the thickness of the cement was  $208.8 \pm 3.8 \mu\text{m}$ , and the thickness of the dentin tubules was  $5.82 \pm 0.06 \mu\text{m}$ .

From the 7th day of the experiment, swelling was observed in the pulp part of the tooth. The results of the morphological examination showed that the thickness of the enamel layer of the hypothyroid rats was  $3232 \pm 4.2 \mu\text{m}$ , the thickness of the

dentin was  $616.4 \pm 27.6 \mu\text{m}$ , the thickness of the predentin was  $22.6 \pm 1.1 \mu\text{m}$ , the pulp was  $805.9 \pm 34.4 \mu\text{m}$ , the cementum thickness was  $184.8 \pm 14.5 \mu\text{m}$ , dentin canals were  $5.2 \pm 0.07 \mu\text{m}$ . The morphometric parameters of the tooth were found to be smaller compared to the control group, in which the thickness of the enamel layer - by 12% (Fig. 1), the thickness of the dentin by 11%, the thickness of the predentin by 14%, the thickness of the pulp by 15%, the thickness of the cementum by 13% and the thickness of the dentin tubules by 12% was observed to decrease to.

Diagram 1.

**Age-related changes in the cementum part of the tooth against the background of hypothyroidism**

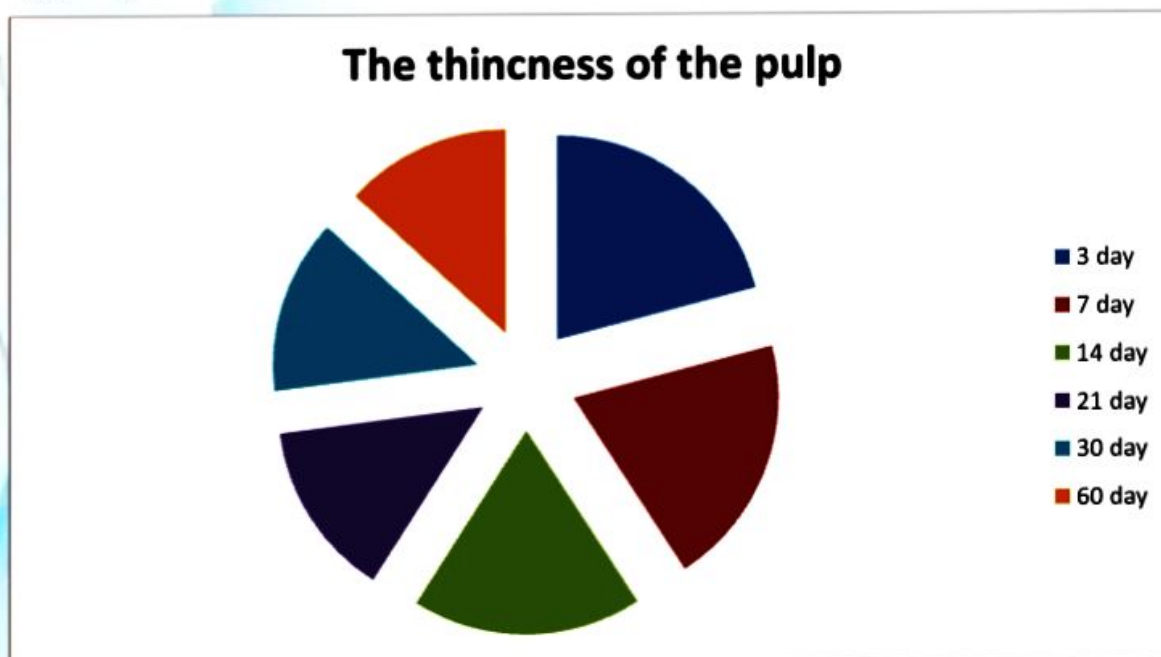


By the 14th day of the experiment, signs of blood circulation and swelling were observed in the pulp part of the teeth of rats. It was observed that the thickness of the enamel layer of the tooth decreased by 15%, the thickness of the dentin by 17% (Fig. 2), the thickness of the predentin by 18%, the thickness of the pulp by 15%, the thickness of the cementum by 16%, and the thickness of the dentin tubules by 14%. By the 21st day of the experiment, it was found that swelling spread in the pulp of the teeth, hemodynamic changes increased. It was observed that the thickness of the enamel layer of the tooth decreased by 18%, the thickness of the

dentin by 21%, the thickness of the predentin by 16%, the thickness of the pulp by 27% (Fig. 3), the thickness of the cementum by 23%, and the thickness of the dentin tubules by 17%.

Diagram 2

**Age-related changes in the pulp part of the tooth against the background of hypothyroidism**



By the 30th day of the experiment, there was increased swelling in the pulp of the teeth, signs of small bleeding. It was observed that the thickness of the enamel layer of the tooth decreased by 21%, the thickness of the dentin by 18%, the thickness of the predentin by 19%, the thickness of the pulp by 22%, the thickness of the cementum by 17%, and the thickness of the dentin tubules by 17%.

By the 60th day of the experiment, it was observed that the thickness of the enamel layer of the tooth decreased by 23%, the thickness of the dentin by 20%, the thickness of the predentin by 16%, the thickness of the pulp by 21%, the thickness of the cementum by 18%, and the thickness of the dentin tubules by 15%. During this period, it was found that swelling spread in the pulp part of the teeth, hemodynamic changes increased.

By the 90th day of the experiment, it was found that swelling spread in the pulp of the teeth, hemodynamic changes increased. It was observed that the thickness of the enamel layer of the tooth decreased by 22%, the thickness of the



dentin by 29%, the thickness of the predentin by 19%, the thickness of the pulp by 28%, the thickness of the cementum by 25%, and the thickness of the dentin tubules by 17%.

The following were observed histologically in the teeth of 3-day-old rats in the control group. Anatomically, enamel is located in the crown of the tooth. In it, we can see enamel prisms made of extremely fine fibrillar network. Each prism consists of 5-6 faceted structures. Also, the enamel surface is covered with Nasmit veil.

Dentin covers the main part of the tooth and consists of dentin canals. In dentin tubules, there are rows of odontoblasts. In addition, we also see collagen fibrils. Some scientists believe that dentin is also bone, but it is much more altered and hardened. In addition, there are collagen fibers in the dentin layer, which are located radially and there are also tangential fibers between them.

Cement is anatomically located in the root and neck parts of the tooth. Histologically, cellular and non-cellular cement are distinguished. Acellular cementum consists of collagen fibers and an amorphous substance that covers the root of the tooth. At the same time, we can see Sherpey fibers in it. In acellular cement, collagen fibers are arranged in a disorderly manner, so it resembles roughened bone. The pulp is located in the cavity of the tooth crown and in the root canals, and it is divided into 3 zones: peripheral, intermediate, central. As a result of the histological examination, it was found that the multicellular pear-shaped cells in the pulp are composed of odontoblasts (dentinoblasts).

### **Conclusion:**

1. Changes in the hard substance of the tooth against the background of hypothyroidism are manifested by the swelling of the pulp, the expansion of the dentine tubules, the appearance of defects in the enamel, and the appearance of signs of lysis in the cement part.

2. Changes in the 14th day of the first postnatal ontogenesis are manifested by a decrease in the thickness of the elements of the hard part of the tooth.



3. Therefore, mercazolil drug can artificially induce hypothyroidism and its doses are measured in relation to body weight at each age.

### REFERENCES

1. AKHMEDOVA S.M., NORTAEVA N.A., NORTAEV A.B. MORPHOLOGICAL CHANGES IN THE TEETH OF ADOLESCENT CHILDREN WITH HYPOTIREOSIS // COLLECTION OF MATERIALS OF THE SCIENTIFIC AND PRACTICAL CONFERENCE WITH INTERNATIONAL PARTICIPATION, DEDICATED TO THE 100TH ANNIVERSARY OF THE TASHKENT MEDICAL ACADEMY, "100 YEARS OF THE TASHKENT MEDICAL ACADEMY – THE ERA OF GREAT ACHIEVEMENTS AND DISCOVERIES". TASHKENT, 2022 -P. 199-200  
MIRZAMUKHAMEDOV O.KH., AKHMEDOVA S.M. MODELIROVANIE TOKSICHESKOGO MYOCARDITA NA FONE HYPOTHYROIDISM // MEDICAL BULLETIN. - TASHKENT, 2019, NO. 5. - B. 56–59.
2. MIRSHAROPOV U.M.; USMONOV R.J.; TESHAEV O.R. MIRZAMUHAMEDOV O.KH. AKHMEDOVA S.M. ET AL. MORPHOLOGICAL CHANGE OF MYOCARDIUM IN HYPOTHYROIDISM // CENTRAL ASIA JOURNAL OF MEDICINE – 2020, № 1 – P. 71–83.
3. MIRZAMUKHAMEDOV O.KH., MIRSHAROPOV U.M., SODIKOVA Z.SH., AKHMEDOVA S.M., KHATAMOV A.I., MIRZABEKOVA O.A. ESPECIALLY THE DEVELOPMENT OF MYOCARDITIS IN HYPOTHYROIDISM IN POSTNATAL ONTOGENESIS // INDIAN JOURNAL OF FORENSIC MEDICINE & TOXICOLOGY – 2020, VOL. 14, № 4 – P. 7737–7745.
4. NORTAEVA N.A., AKHMEDOVA S.M., NORTAEV A.B. MORPHOLOGICAL CHANGES IN THE TEETH ADOLESCENT CHILDREN WITH HYPOTIREOSIS // PROBLEMS OF BIOLOGY AND MEDICINE. - SAMARKHAND, 2022. - P 270. ISSN 2182-5674, [HTTPS://DOI.ORG/10.38096/2181-5674.2022](https://doi.org/10.38096/2181-5674.2022)



5. NORTAEVA N.A., NORTAEV A.B. MORPHOLOGICAL CHANGES IN TEETH AGAINST THE BACKGROUND OF EXPERIMENTAL HYPOTHYROIDISM // TOPICAL ISSUES OF MODERN SCIENTIFIC RESEARCH.-DUSHANBE 2022.-P 168.
6. NORTAEVA N.A., NORTAEVA.B. MORPHOLOGICAL CHANGES IN THE TOOTH IN EXPERIMENTAL HYPOTHYROIDISM // ISSUES OF INNOVATIVE DEVELOPMENT OF SCIENCE, EDUCATION AND TECHNOLOGY. - ANDIJAN, 2022.-P 273-275
7. NORTAEVA N.A., NORTAEV A.B., AKHMEDOVA S.M. TO STUDY THE MORPHOLOGICAL CHANGES IN THE TOOTH AGAINST THE BACKGROUND OF EXPERIMENTAL HYPOTHYROIDISM // CURRENT PROBLEMS OF MICROBIOLOGY. - TASHKENT, 2022 -P. 148-152
8. NORTAEVA N.A. MORPHOLOGICAL CHANGES IN TEETH AS A RESULT OF MALNUTRITION IN PRESCHOOL CHILDREN // PROCEEDINGS OF THE CONFERENCE DEDICATED TO THE 95TH ANNIVERSARY OF ACADEMICIAN, MORPHOLOGIST, SCIENTIST KOMILJON ZUFAROV. - TASHKENT, 2021 -P. 34-36
9. NORTAEVA N.A., AKHMEDOVA S.M. MORPHOLOGICAL CHANGES IN THE DENTAL IN EXPERIMENTAL HYPOTIREOSIS // COLLECTION OF MATERIALS OF THE SCIENTIFIC AND PRACTICAL CONFERENCE OF YOUNG SCIENTISTS WITH INTERNATIONAL PARTICIPATION, DEDICATED TO THE 100 TH ANNIVERSARY OF THE TASHKENT MEDICAL ACADEMY, «INNOVATIVE APPROACHES IN MEDICINE». TASHKENT, 2022 -P. 51
10. NORTAEVA N.A., AKHMEDOVA S.M., NORTAEV A.B. ANTHROPOMETRIC INDICATORS OF THE MAXILLOFACIAL SYSTEM IN SCHOOL-AGED CHILDREN WITH HYPOTHYROIDISM // MODERN SCIENTIFIC RESEARCH TOPICAL ISSUES, ACHIEVEMENTS AND INNOVATIONS.СОВРЕМЕННЫЕ НАУЧНЫЕ ИССЛЕДОВАНИЯ



**АКТУАЛЬНЫЕ ВОПРОСЫ, ДОСТИЖЕНИЯ И ИННОВАЦИИ. ПЕНЗА, 2023  
–Р. 153. ISBN 978-5-00173-707-0**

**11. NORTAEVA N.A., AKHMEDOVA S. M., NORTAEV A.B., RAJABOV  
B.M. CHANGES IN THE FACE-JAW SYSTEM OF EXPERIMENTAL  
HYPOTHYROIDISM // TEXAS JOURNAL OF MEDICAL SCIENCE  
[HTTPS://ZIENJOURNALS.COM](https://zienjournals.com) 2023 –Р. 61-64 ISSN NO: 2770-2936**