

ANATOMY OF THE BACK MUSCLES

Kattaxodjayeva Dinara Utkurxodjayevna

Senior Lecturer, Tashkent Medical Academy

Abstract: The work examines the anatomy of the back muscles, which are divided into superficial and deep. The back area, occipital parts of the neck and the contour of the shoulder blades are studied. It is shown that the trapezius muscle has the shape of a triangle, the latissimus dorsi is flat, the small rhomboid muscle has a connective tissue layer, and the muscle that lifts the scapula is rotator.

Key words: anatomy, muscles, back, shape, triangular, occipital, flat, rhomboid, connecting, deep, superficial, limbs, scapula.

A muscle spasm in the back causes pain, statistically, in every person at least once in their life. Most often, it occurs in the lower back, as this is the most mobile part of the spine. Pain does not just occur: it often accompanies a number of diseases of the musculoskeletal system. The spinal column is the frame of our body and protects the spinal cord from damage. Between the vertebrae there is a kind of shock absorber - the intervertebral disc. The processes of the vertebrae are connected to each other by facet joints and form an opening through which nerve tissue passes.

The back muscles and ligaments support the human body in a horizontal position and provide movement.

The muscles of the back (Fig. 1), muscoli dorsi, are divided into superficial and deep.

I. Superficial muscles of the back.

a) muscles of the back related to the upper limb:

1. Trapezius muscle, m. trapezius.
2. Latissimus dorsi muscle, m. latissimus dorsi.
3. Large and small rhomboid muscles, mm. rhomboidei major et minor.
4. The muscle that lifts the scapula, m. levator scapulae.

b) Rib muscles:

5. Superior posterior serratus muscle, m. serratus posterior superior.
6. Lower back serrated muscle, m. serratus posterior inferior.

P. Deep (intrinsic) muscles of the back.

a) Long:

1. Splenius capitis muscle, m. splenius capitis.
2. Splenius cervicis muscle, m. splenius cervicis.
3. The muscle that straightens the trunk, m. erector trunci.
4. Transverse spinal muscle, m. transversospinalis.

b) Short:

1. Interspinous muscles, mm. interspinales.
2. Intertransverse muscles, mm. intertransversarii.
3. Muscles that raise the ribs, mm. levatores costarum.
4. Suboccipital group. The deep muscles of the back are covered by the thoracolumbar fascia, fascia thoracolumbalis.

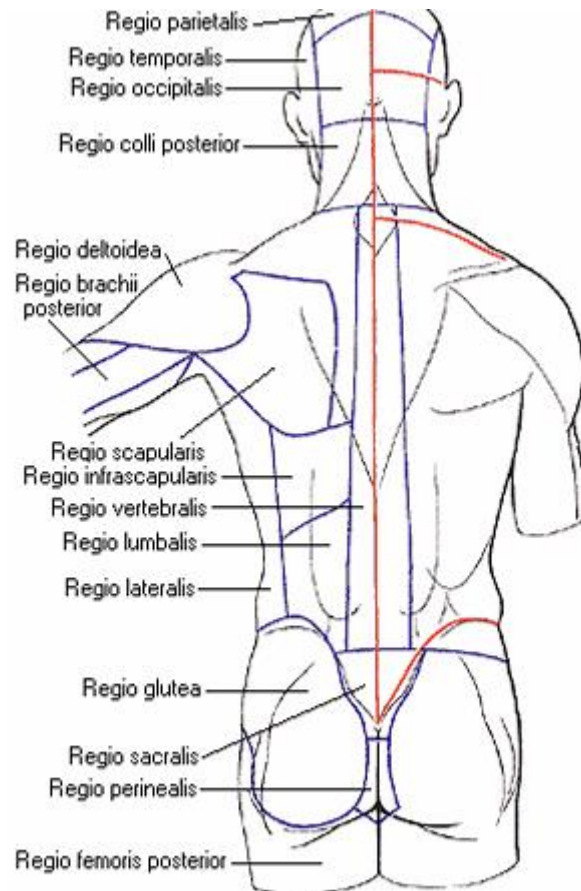


Figure 1. Back areas.

The following regions of the back, *regiones dorsi*, are distinguished: the posterior region of the neck, *regio colli posterior*, unpaired, occupies the posterior, occipital parts of the neck; the vertebral region, *regio vertebralis*, unpaired, corresponds to the contours of the spinal column; the scapular region, *regio scapularis*, corresponds to the contours of the scapula; the subscapular region, *regio infrascapularis*, right and left, is located below the scapula; the lumbar region, *regio lumbalis*, right and left, is limited above by the 12th rib, below by the iliac crest; the sacral region, *regio sacralis*, unpaired, corresponds to the contours of the sacrum [1, 2].

When examining the back areas, a longitudinal groove of the back, *sulcus dorsi*, is visible along the midline, along which the spinous processes of the protruding vertebra and all the underlying vertebrae can be felt. On the sides of this groove, the relief of the muscle that straightens the trunk is visible, and in the upper section, in addition, the contours of the scapula and the spine on it, *spina scapulae*, are noticeable. The upper edge of the scapula corresponds to the 2nd rib, the lower angle - to the 7th rib.

When the well-developed muscles are contracted, a depression is noticeable in the upper back - a diamond-shaped area, in the center of which lies the *processus spinosus* of the protruding vertebra. This depression corresponds to the *trapezius* tendon expanded in this area. In the lower back, the iliac crests are accessible for palpation. Here, another diamond-shaped depression is indicated, limited at the top by the *processus spinosus* of the 5th lumbar vertebra, on the sides by the *spina iliaca posterior superior*, and at the bottom by the *coccyx*.

Superficial muscles of the back.

1. The trapezius muscle, *m. trapezius*, is a flat, wide muscle, occupies a superficial position in the back of the neck and in the upper back. The trapezius muscle has the shape of a triangle, with its base facing the spinal column, and its apex - to the acromion of the scapula; the trapezius muscles of both sides together have the shape of a trapezoid. The muscle originates from the protuberantia occipitalis externa, linea nuchae superior, ligamentum nuchae and ligamentum supraspinale of all thoracic vertebrae . The tendon bundles of the muscle are short and only in the region of the lower cervical and upper thoracic vertebrae, reaching a great length, form a rhomboid tendon platform. The muscle bundles converge radially toward the scapula and attached to the spina scapulae, acromion, and pars acromialis claviculae. Action: by contracting with all bundles, the muscle brings the scapula closer to the spinal column; by contracting with the upper bundles, it raises the scapula, and with the lower bundles, it lowers it. When fixing the scapula, both trapezius muscles pull the head back, and with unilateral contraction, the muscle tilts the head to the corresponding side. Innervation: ramus externus n. accessorii and nn. cervicales (C3 - C4). Blood supply: transversa coli, occipitalis, suprascapularis, intercostales.

2. Latissimus dorsi, *m. latissimus dorsi* , flat; this muscle lies superficially in the lower back, but its upper bundles in the initial part are covered by the trapezius muscle. It starts from the spinous processes of the 5-6 lower thoracic vertebrae, from the superficial (posterior) leaflet of the lumbosacral fascia, from the posterior part of the labium externum cristae iliacaе and from the 4 lower ribs. Outwardly from the tendon bundles of the described muscle, between them and the posterior edge of the external oblique muscle of the abdomen, *m. obliquus abdominis externus*, and below - crista iliaca, the lumbar triangle, trigonum lumbale is formed; the bottom (anterior wall) is *m. obliquus abdominis internus*. Above this triangle is a small diamond-shaped area, covered from behind by *m. latissimus dorsi* and is limited above by the 12th rib and the lower edge of *m. serratus posterior inferior*, medially by *m. erector trunci*, laterally by the upper edge of *mm. obliqui abdominis intemus*, its bottom (anterior wall) is formed by the aponeurosis of the transverse abdominal muscle. The upper bundles of the latissimus dorsi, directed laterally, the lower ones - obliquely upward and laterally, cover the posterior surface of the lower ribs. Here the muscle receives additional bundles in the form of 3-4 teeth, and also covers the lower angle of the scapula and the lower edge of the large round muscle, *m. teres major* (sometimes receiving an additional bundle).

Further, the muscle, forming the posterior wall of the axillary fossa, approaches the humerus and ends at the crista tuberculi minoris humeri. Here is the bag of the latissimus dorsi muscle, bursa subtendinea *m. latissimi dorsi*. Action: brings the shoulder to the body and pulls the upper limb back to the midline, rotating it inward (pronatio). When the upper limb is strengthened, it brings the body closer to it or takes part in the displacement of the lower ribs upward during respiratory movement, thus being an auxiliary respiratory muscle. Innervation: n. thoracodorsalis (C 7 , C 8). Blood supply: aa. thoracodorsalis, circumflexa humeri, intercostales.

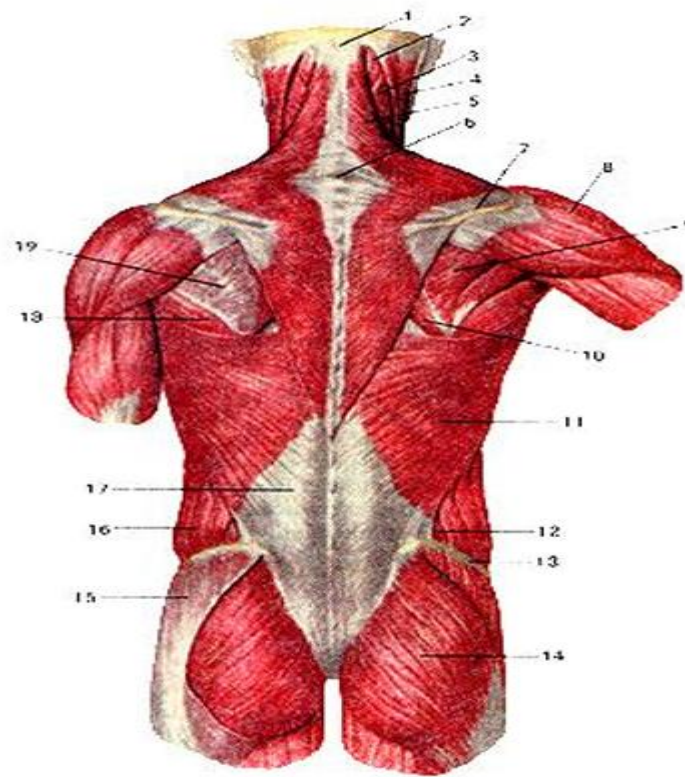


Figure 2. Superficial muscles of the back. 1 - external occipital protuberance; 2 semispinalis capitis; 3 - splenius capitis; 4 - sternocleidomastoid muscle; 5 - trapezius muscle; 6 - spinous process of the VII cervical vertebra; 7 - spine of the scapula; 8 - deltoid muscle; 9 - infraspinatus muscle; 10 - rhomboid major muscle; 11 - latissimus dorsi; 12 - lumbar triangle; 13 - wing of the ilium; 14 - gluteus maximus; 15 - gluteal fascia; 16 - external oblique abdominal muscle; 17 - aponeurosis of the latissimus dorsi; 18 - teres major muscle; 19 - infraspinatus fascia.

3. The large rhomboid muscle, *m. rhomboideus major*, a muscle of the second layer, is located under the trapezius muscle between the shoulder blades and has the appearance of a flat, wide, rhombus-shaped plate. It originates from the spinous processes of the 4 upper thoracic vertebrae. Its bundles are directed laterally and slightly downwards and are attached to the medial edge of the scapula.

4. The rhomboid minor muscle, *m. rhomboideus minor*, originates from the spinous processes of the two lower cervical vertebrae and inserts on the medial border of the scapula. Both rhomboid muscles are often separated from each other by a small layer of connective tissue. Action: brings the scapula closer to the spinal column along an oblique line directed toward the middle and upward. Innervation: *n. dorsalis scapulae* (C4-C6). Blood supply: *aa. transversa colli, suprascapularis, intercostales* [3-17].

5. The muscle that lifts the scapula, *m. levator scapulae*, is a muscle of the second layer, oblong, thickened, located in the lateral parts of the back of the neck under *m. trapezius*. It begins with four separate teeth from the posterior tubercles of the transverse processes of the upper 4 cervical vertebrae and, directed downwards and somewhat laterally, is attached to the upper part of the medial border of the scapula and its upper angle. Action: raises the scapula,



especially its upper angle, thereby imparting a rotational movement that shifts the lower angle towards the spinal column; with a strengthened scapula, it tilts the cervical part of the spinal column backwards and towards itself. Innervation : n. dorsalis scapulae (C4, C 5). Blood supply : aa . transversa colli, cervicalis superficialis, cervicalis ascendens.

6. Upper back serrated muscle , m. serratus posterior superior, muscle thin , covered diamond-shaped muscle . It begins from lower parts of the ligamentum nuchae and spinous shoots two lower cervical And two top chest vertebrae . Its bundles are directed obliquely downwards and laterally and are attached by four teeth to the outer surface of the II-V ribs, somewhat lateral to their angles. Action: raises the upper ribs, participating in the act of inhalation. Innervation: nn. intercostales (Th1-Th4). Blood supply: aa. intercostales, cervicalis profunda.

7. The lower posterior serratus muscle, m. serratus posterior inferior, like the previous one, is flat, thin, and located under m. latissimus dorsi. It originates from the superficial leaflet of the fascia thoracolumbalis at the level of the two lower thoracic and two upper lumbar vertebrae. Its bundles are directed obliquely upward and laterally and are attached with four teeth to the outer surface of the four lower ribs. Action: lowers the lower ribs, participating in the act of breathing. Innervation: nn. intercostales (Th9-Th12). Blood supply: aa. intercostales.

References

1. М.Р. Сапина. Анатомия человека в 2-том. М.: 1986.
2. Синельников Р.Д. , Синельников Я.Р. Атлас анатомии человека. В 4-х томах. М.: 1989 - 1990.
3. М.Р. Сапина. Анатомия человека в 2-том. М.: 1986.
4. Синельников Р.Д. , Синельников Я.Р. Атлас анатомии человека. В 4-х томах. М.: 1989 - 1990.
5. Elmurotova D.B., Nishonova N.R., Kulueva F.G., Uzoqova G.S., Xo‘jamberdiyeva J.N., Jo‘rayeva Sh.A. Mashait: islamic interpretation of the greek philosophical heritage // South Eastern European Journal of Public Health (SEEJPH), (ISSN: 2197-5248) V.XXV, S2, 2024, Posted:05-12-2024, P.516-522, <https://www.seejph.com/index.php/seejph>
6. Shodiev A.A., Mussaeva M.A., Nishonova N.R., Elmurotova D.B., Islamova D.X. Improving Structure and Superconductivity of Coated Cuprate Tapes by Irradiation with Electrons and Gamma-Rays // Nanotechnology Perceptions, ISSN 1660-6795, V.20, N.7 (2024), P. 209-126, <https://nanontp.com/index.php/nano/article/view/3822>
7. Elmurotova D.B., Odilova N.J., Jumanov Sh.E. Semmelweis against puberner fever in hungary // Western European Journal of Linguistics and Education, V.2, Iss1, January-2024 ISSN (E): 2942-190X, P.56-59, Germany. <https://westerneuropeanstudies.com/index.php/2/article/view/255>
8. Элмуротова Д.Б., Элмуратов Э.Б. Исследование и совершенствование техники и технологии по освоению скважин в сложных горно-геологических условиях на месторождениях Республики Узбекистан // Лучшие интеллектуальные исследования, Ч-13, Т.5, Январь-2024, С.11-23, Россия. <http://web-journal.ru/index.php/journal/issue/view/89>



9. Elmurotova D.B., Sayfullayeva D.I., Isroilova Sh.A. Terms of medical information system, World Bulletin of Public Health (WBPH), V.34, May, P.91-92, 2024 ISSN: 2749-3644, Berlin. <https://www.scholarexpress.net>
10. Elmurotova D.B, Majlimov F.B., Zuparov I.B., Kayumova K.S., Xudoyberdiyev B.A. A modern approach to hand hygiene in medicine // European Journal of Humanities and Educational Advancements (EJHEA), V.5 N.05, May 2024 ISSN: 2660-5589, P.51-53, Spain. <https://www.scholarzest.com>
11. Elmurotova D., Arzikulov F., Egamov S., Isroilov U. Organization of direct memory access // Intent Research Scientific Journal-(IRSJ), ISSN (E): 2980-4612, V.3, Is.10, October – 2024, P. 31-38., Philippines, <https://intentresearch.org/index.php/irsj/article/view/345>
12. Elmurotova D., Arzikulov F., Izzatullayev I., Olimov A., Abdurahmonov J. The role of remote diagnostics in medicine // World Bulletin of Public Health (WBPH), V.39, October 2024, ISSN:2749-3644, P.102-105. Germany, <https://scholarexpress.net/index.php/wbph/article/view/4664>
13. Elmurotova D., Fayziyeva N.A., Urmanbekova D.S., Bozorov E.H. Implementation of the method of teaching x-ray therapy in higher educational institutions // **Web of Teachers: Inderscience Research**, V.2, Issue 10, October-2024, ISSN (E):2938-379X, P.18-23. Spain. <https://webofjournals.com/index.php/1/article/view/1868>
14. Elmurotova D.B., Esanov Sh.Sh., Abduraxmonov S.A., Ulug'berdiyev A.Sh., Umarov J.S. Medical device reliability and measuring instrument specifications // Eurasian Journal of Engineering and Technology, EJET, V.34, October-7, 2024, ISSN: (E) 2795-7640, P.10-13, Belgium. <https://geniusjournals.org/index.php/ejet>
15. Shodiev A.A., Mussaeva M.A., Elmurotova D.B. Magnetic resistance and mobility of carriers of HTSC – YBCO tapes irradiated with 5 MeV electrons // Eurasian Journal of Physics, Chemistry and Mathematics, EJPCM, V.35, October-26, 2024, ISSN: 2795-7667, P.25-33, Belgium. <https://geniusjournals.org/index.php/ejpcm/article/view/6393>
16. Elmurotova D.B., Fayziyeva N.A., Odilova N.J. Properties of electron and neutron therapy // Web of Medicine: Journal of medicine, practice and nursing, V.2, Issue 10, October-2024, ISSN (E): 2938-3765, P.137-141, Spain.
17. Elmurotova D.B., Yoqubboyeva E.Z., Orifqulova M.F., Imanova L.N. Application of computer technologies in medicine // Western European Journal of Medicine and Medical Science, V.2, Issue 11, ISSN (E): 2942-1918, November-2024, P.1-12. Germany. <https://westerneuropeanstudies.com/index.php/3>