





TASHKENT MEDICAL ACADEMY

100 TMA
ANNIVERSARY



Journal of Educational and Scientific Medicine



Issue 6 | 2025



OAK.UZ
Google Scholar

Science Education Commission of the Cabinet
Ministry of the Republic of Uzbekistan

ISSN: 2181-3175

Pathomorphology of Internal Organs in Experimental Interstitial Lung Injury under Combined Treatment

Sabirova R.A., Tursunov D.Kh., Tursunov Kh.Z., Rakhmanov A.Kh.

ABSTRACT

This article presents the results of a study on morphological changes in internal organs in a rat model of interstitial pneumonia under combined treatment with ecdysten, acetylcysteine, and polyoxidonium. The data revealed a significant reduction in inflammatory and destructive changes in the lungs, liver, and kidneys. Combined therapy promoted restoration of normal tissue structure and alleviated signs of oxidative stress and hypoxic damage. The findings confirm the effectiveness of pharmacological correction in interstitial pneumonia and highlight the need for further research.

Keywords: *interstitial pneumonia, combined treatment, ecdysten, polyoxidonium, acetylcysteine, pathomorphology, rats.*

INTRODUCTION

Interstitial lung diseases, including interstitial pneumonia (IP), represent one of the most important challenges in modern medicine, as they are associated with chronic inflammation, fibrosis, and respiratory failure. The pathogenesis of IP is complex and involves activation of the immune system, systemic inflammatory response, oxidative stress, and disturbances in lipid and protein metabolism [2]. Studying the molecular and morphological basis of these processes is essential for identifying effective therapeutic approaches [1].

One of the widely used approaches for modeling interstitial lung injury is chronic exposure to tobacco smoke in the Kurlandsky chamber, which ensures controlled delivery of tobacco combustion products into the airways of laboratory animals [3]. The Kurlandsky chamber is equipped with a system for monitoring

smoke concentration and automatic cigarette combustion, which allows for the standardization of respiratory exposure and the reproduction of morphological and functional changes characteristic of chronic airway pathology [5].

In modern experimental pulmonology, combined treatment is gaining increasing importance. The combination of antioxidants, immunomodulators, and adaptogens makes it possible not only to influence the inflammatory process, but also to prevent the development of systemic complications, including damage to the kidneys, liver, and cardiovascular system [4]. The combination of ecdysten, acetylcysteine, and polyoxidonium has potential to reduce inflammation, alleviate oxidative stress, and restore homeostasis [6].

The aim of this study was to investigate morphological changes in internal organs during experimental inter-

stitial lung injury under conditions of combined treatment.

EXPERIMENTAL MODEL OF INTERSTITIAL LUNG INJURY

Experimental interstitial lung injury was reproduced in 164 outbred white rats weighing 150–200 g by chronic exposure to tobacco smoke in a Kurlandsky chamber for 60 days [3]. Smoke was generated by burning Pall Mall cigarettes (Uzbekistan), which provided a stable concentration of nicotine and combustion products. The control group consisted of intact animals.

After completion of the exposure period, the animals were decapitated, and samples of the lungs, liver, and kidneys were collected for subsequent pathomorphological analysis, including both macroscopic and microscopic evaluation.

ADMINISTERED PREPARATIONS

For 15 days, the animals received the following agents per os:

- Ecdysten — 2.4 mg/100 g body weight;
- Acetylcysteine — 1.9 mg/100 g body weight;
- Polyoxidonium — 33.3 mg/100 g body weight;
- Combination of all three agents.

MORPHOLOGICAL METHODS OF INVESTIGATION

To compare the effects of the agents, morphological studies of internal organs were carried out at the Republican Pathoanatomical Center of the Ministry of Health of the Republic of Uzbekistan (Director — Prof. D.A. Nishanov, Consultant — Prof. Kh.Z. Tursunovs). During autopsy, internal organs were excised, and tissue fragments measuring 0.5 × 0.5 cm were obtained.

The tissues were fixed in 10% neutral buffered formalin, dehydrated in graded ethanol, and embedded in paraffin. Histological sections of 5 μm thickness were prepared on a Leica rotary microtome and stained with hematoxylin and eosin. Cell nuclei were stained blue-black, and the cytoplasm appeared dark violet.

Ethical Standards. The study was conducted in accordance with ethical principles and international guidelines for the care and use of laboratory animals.

RESULTS

Histological examination of internal organs under combined treatment of experimental pneumonia revealed the following findings.

In the lungs, under treatment with ecdysten, the alveoli were air-filled, with some emphysematous dilation and septal rupture in individual alveoli. Perivascular and peribronchial sclerosis persisted, along with focal mononuclear inflammatory infiltration and vascular congestion (Fig. 1).

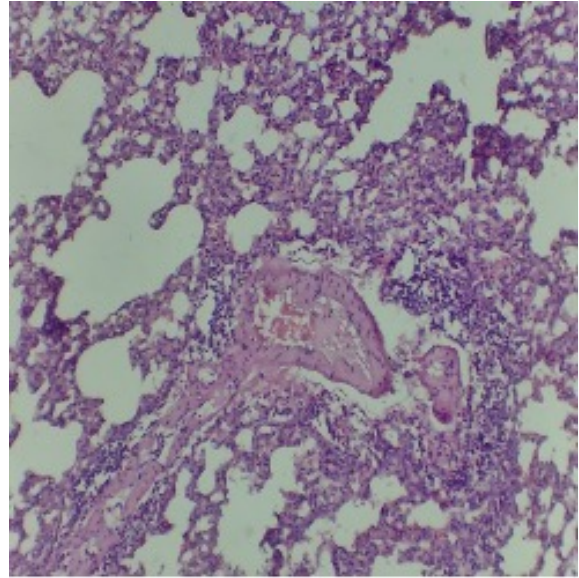


Fig. 1. Staining: hematoxylin and eosin. Magnification 10x10.

Under treatment with polyoxidonium, peribronchial sclerosis and focal interstitial sclerosis of the tissue were preserved. The bronchial epithelium was high columnar, with proliferation and papillary formations (Fig. 2).

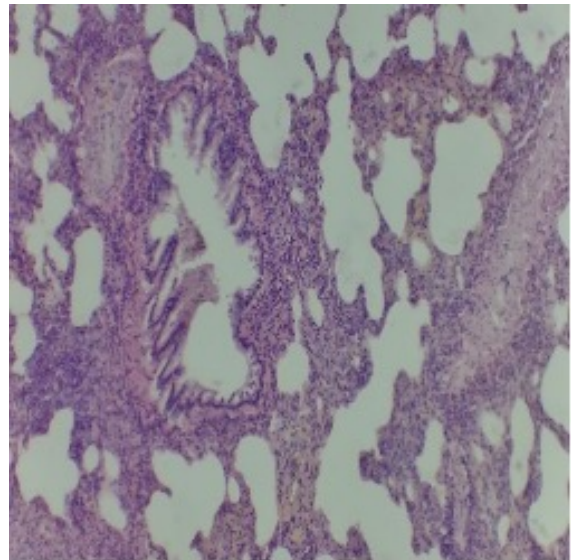


Fig. 2. Staining: hematoxylin and eosin. Magnification 10x40.

Under treatment of experimental pneumonia with acetylcysteine (ACC), the lungs showed moderate peribronchial sclerosis with focal inflammatory peribronchial and perivascular infiltration, as well as proliferation of the bronchial epithelium. The alveoli were pneumotized (Fig. 3).

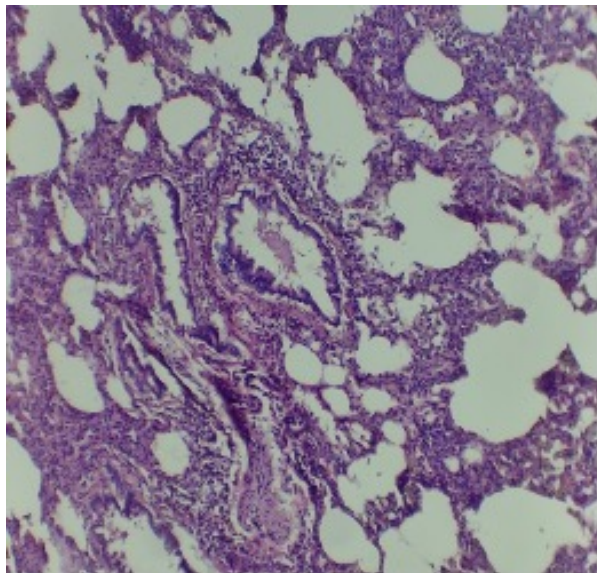


Fig. 3. Staining: hematoxylin and eosin. Magnification 10x10.

Combined treatment of interstitial lung injury with Ecdysten + Polyoxidonium + ACC produced a pronounced effect — the histological structure of the lungs did not differ from normal: the alveoli were air-filled, interalveolar septa were thin, and no signs of sclerosis or inflammatory infiltration were detected (Fig. 4).

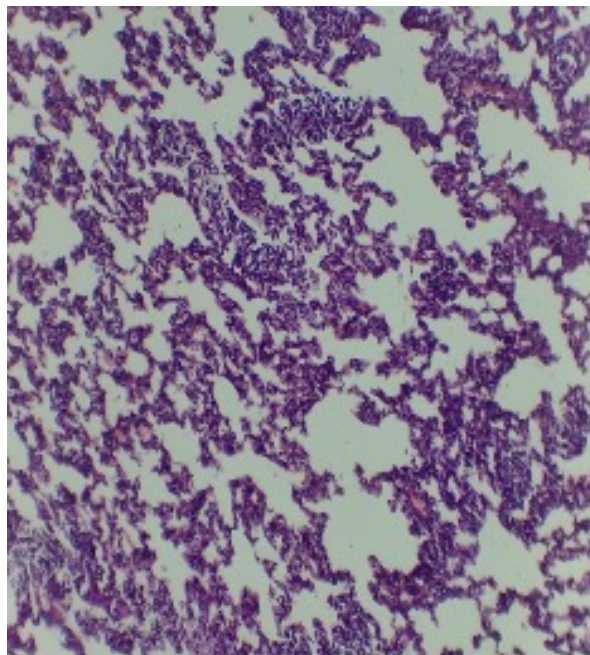


Fig. 4. Staining: hematoxylin and eosin. Magnification 10x4.

Examination of the liver structure in experimental lung injury demonstrated preserved morphology under treatment: portal triads were clearly expressed, and the lobular and trabecular structure of hepatocytes was maintained (Fig. 5).

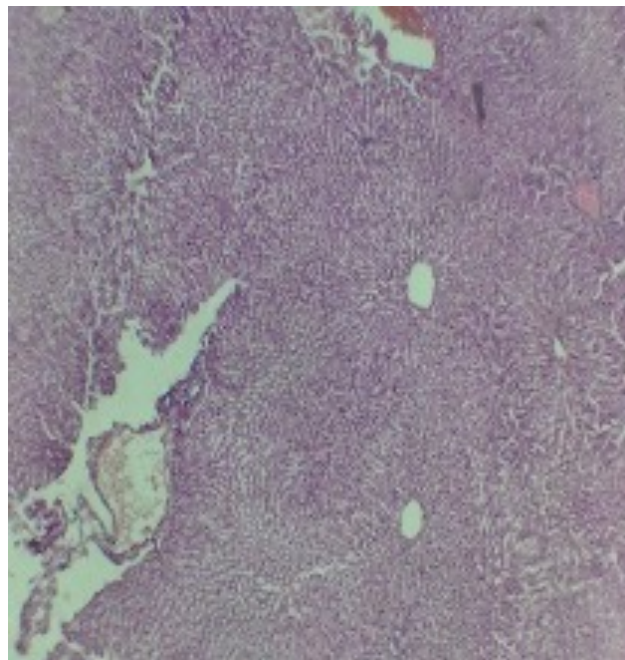


Fig. 5. Staining: hematoxylin and eosin. Magnification 10x4.

However, under treatment with Ecdysten, fine vacuolar degeneration was observed, while more pronounced vacuolar and microvesicular fatty degeneration was identified under Polyoxidonium treatment (Fig. 6).

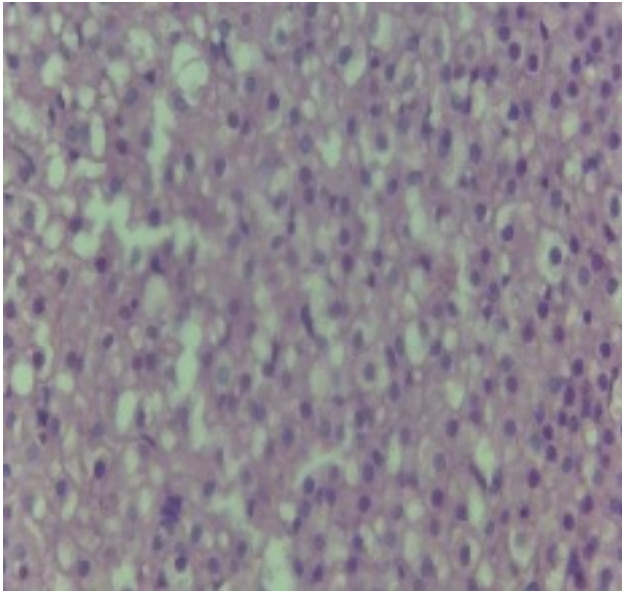


Fig. 6. Staining: hematoxylin and eosin. Magnification 10x10.

In contrast, during ACC therapy, and especially under combined treatment of interstitial lung injury, no significant morphological changes were detected (Figs. 7, 8).

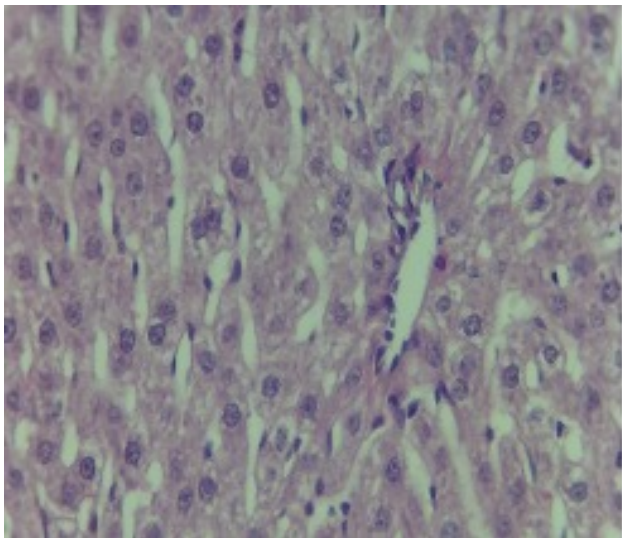


Fig. 7. Staining: hematoxylin and eosin. Magnification 10x40.

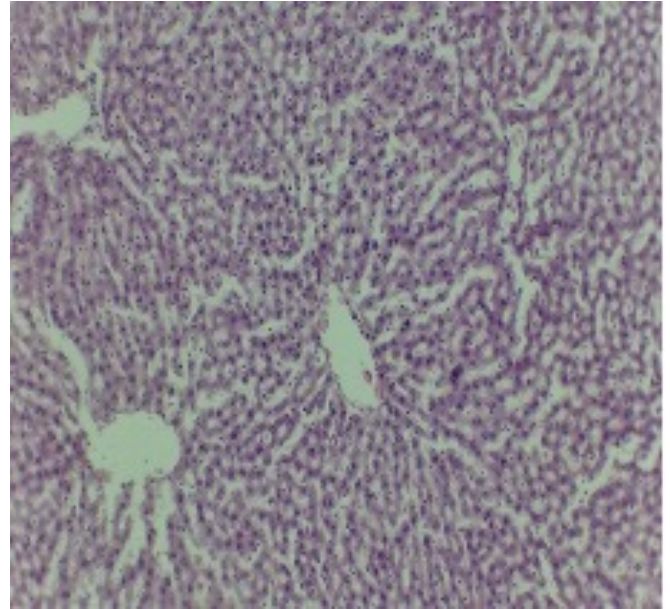


Fig. 8. Staining: hematoxylin and eosin. Magnification 10x4.

Histological examination of the kidneys during the experiment under different treatments revealed that under Ecdysten administration, the structure remained normal: glomeruli had oval to rounded shapes, Bowman's capsule was thin, and their lumina were free. In the tubular apparatus, vacuolar degeneration of the epithelium of convoluted tubules was observed, with cells appearing swollen (Fig. 9).

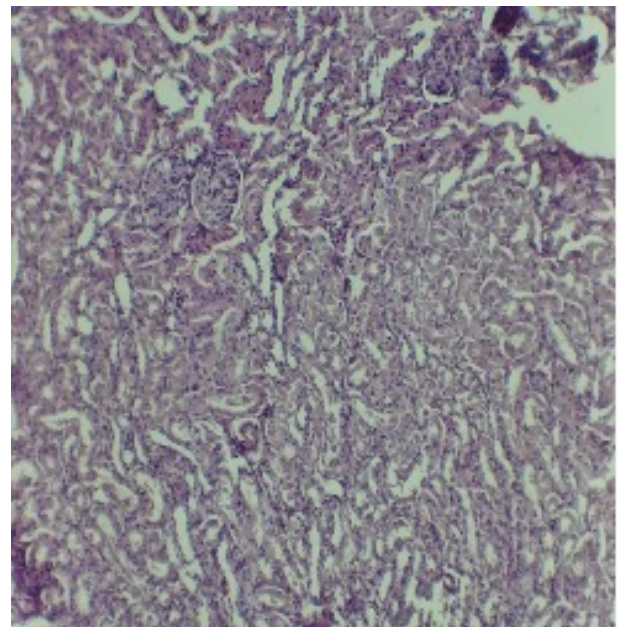


Fig. 9. Staining: hematoxylin and eosin. Magnification 10x4.

Under treatment with Polyoxidonium and ACC, hyperemia of stromal vessels persisted, along with focal vacuolar degeneration of the epithelium of convoluted tubules (Figs. 10, 11).

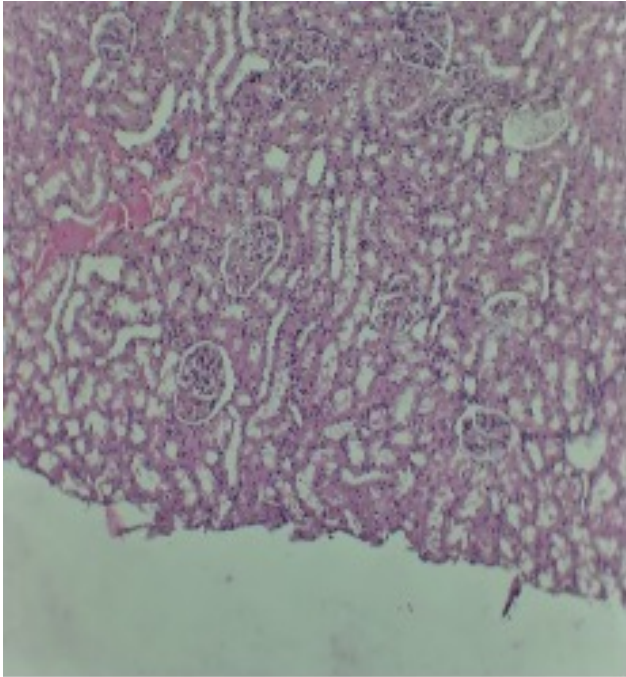


Fig. 10. Staining: hematoxylin and eosin. Magnification 10x4.

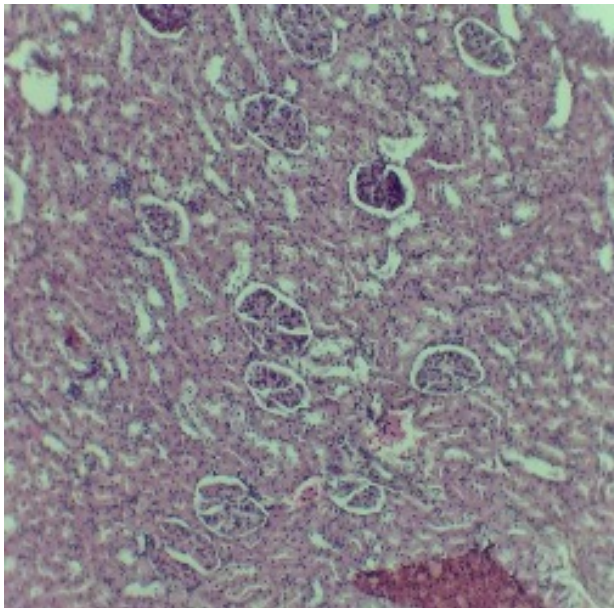


Fig. 11. Staining: hematoxylin and eosin. Magnification 10x4.

Combined treatment resulted in complete restoration of the damaged tubular epithelium; the structural organization did not differ from normal (Fig. 12).

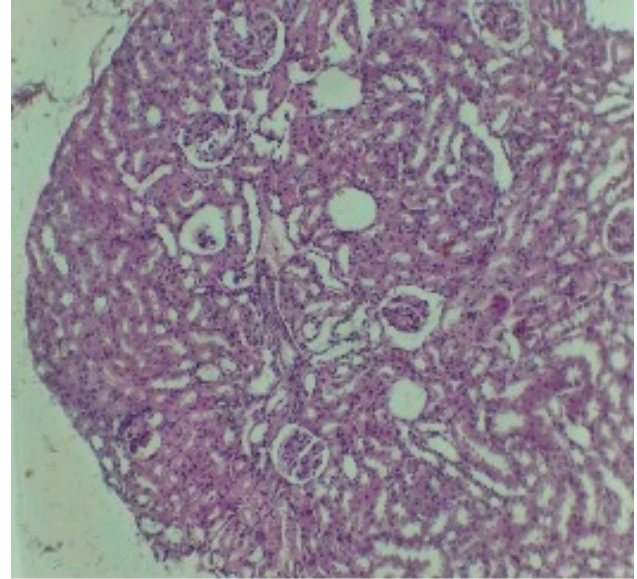


Fig. 12. Staining: hematoxylin and eosin. Magnification 10x4.

CONCLUSION

In rats with interstitial lung injury that received combined treatment (ecdysten, acetylcysteine, and polyoxidonium), a significant reduction in the severity of inflammatory and destructive changes in lung tissue was observed compared to untreated animals.

Lungs: The degree of peribronchial lymphoid infiltration and edema was reduced; the bronchial epithelium preserved its structure with minimal proliferation. Alveolar emphysematous changes were moderate, and signs of interalveolar septal sclerosis were decreased. These findings indicate anti-inflammatory and antioxidant effects of the therapy.

Brain: Vascular congestion and meningeal edema were moderate, while perivascular edema was markedly less than in the untreated group.

Liver and kidneys: Hepatocytes showed less vacuolization and dystrophy. Glomeruli and renal tubules exhibited fewer alterations, indicating a reduction in hypoxic and inflammatory damage.

Heart and spleen: Moderate vascular congestion persisted; however, dystrophic and edematous changes in the myocardium were significantly less pronounced. In the spleen, the structure of follicles was preserved, and the severity of lymphoid hyperplasia was reduced.

In the control group of intact rats, the structure of the lungs, liver, and kidneys showed no pathological changes. Tissue architecture was preserved: alveoli and interalveolar septa appeared normal, capillaries moder-

ately congested, and no destructive signs were observed. These data served as a baseline for comparison.

Under ecdysten treatment, alveoli remained air-filled; however, emphysematous dilatation and rupture of alveolar walls were noted. Signs of perivascular and peribronchial sclerosis, focal mononuclear infiltration, and vascular congestion persisted. In the liver, fine vacuolar degeneration was observed; in the kidneys, vacuolar degeneration of tubular epithelium was present, while glomerular structure was preserved.

Under polyoxidonium treatment, peribronchial and interstitial sclerosis persisted in the lungs; bronchial epithelium showed proliferative activity with papillary formations. In the liver, pronounced vacuolar and fatty degeneration was observed, and in the kidneys — stromal vascular hyperemia and focal degenerative changes in tubular epithelium.

During acetylcysteine therapy, moderate peribronchial sclerosis and focal inflammatory infiltration were preserved in the lungs, along with proliferation of bronchial epithelium. No significant pathological changes were detected in the liver, but vascular hyperemia and focal degenerative changes in tubular epithelium remained in the kidneys.

Combined treatment with ecdysten, acetylcysteine, and polyoxidonium demonstrated the most pronounced therapeutic effect. In the lungs, the histological structure was nearly normal: alveoli were air-filled, interalveolar

septa thin, and no sclerosis or inflammatory infiltration was observed. In the liver, tissue architecture and trabecular arrangement of hepatocytes were preserved without signs of degeneration. In the kidneys, the tubular epithelium was completely restored, and the structure did not differ from the control group. Thus, combined therapy provided almost complete elimination of inflammatory-destructive and dystrophic changes.

REFERENCES

1. Chuchalin A.G. Pulmonology. National guidelines. Moscow: GEOTAR-Media; 2013.
2. Feldman C., Anderson R. Pneumonia as a systemic illness. *Curr Opin Pulm Med.* 2018;24(3):237–243.
3. Kayumov Yu.D., Tadzikhodjaeva Yu.Kh. Experimental model of chronic obstructive pulmonary disease. *Bulletin of the Association of Pulmonologists of Central Asia.* 2020;18(1–4):22–26.
4. Hecker L., et al. NADPH oxidase-4 mediates myofibroblast activation. *Nat Med.* 2009;15(9):1077–1081.
5. Restrepo M., et al. Complication of community-acquired pneumonia. *Semin Respir Crit Care Med.* 2016;37(6):897–904.
6. Aliberti S., et al. Community-acquired pneumonia. *Lancet.* 2021;398(10303):906–919.

EKSPERIMENTAL INTERSTITSIAL O‘PKA SHIKASTLANISHIDA ICHKI A’ZOLARNING PATOMORFOLOGIYASI KOMBINATSIYALANGAN DAVOLASH SHAROITIDA

Sabirova R.A., Tursunov D.X., Tursunov X.Z., Raxmanov A.X.

Toshkent davlat tibbiyot universiteti

Maqolada o‘pkaning eksperimental interstitsial jarohatlanish fonida kalamushlarda ichki a‘zolarining morfologik o‘zgarishlari kombinatsiyalangan davolash (ekdisten, asetilsistein, polioskidoniy) sharoitida o‘rganilgan. Tadqiqot natijalariga ko‘ra, o‘pka, jigar va buyrak to‘qimalarida yallig‘lanish va destruktiv o‘zgarishlar sezilarli darajada kamaygan. Kombinatsiyalangan terapiya to‘qimalarning normal tuzilishini tiklashga, oksidlovchi stress va gipoksik shikastlanish belgilarini kamaytirishga yordam bergan. Olingan natijalar interstitsial pnevmoniyada farmakologik tuzatish usullarining samaradorligini ko‘rsatadi va qo‘shimcha tadqiqotlar uchun zamin yaratadi.

Kalit so‘zlar: interstitsial o‘pka jarohatlanishi, kombinatsiyalangan davolash, ekdisten, polioksidoniy, asetilsistein, patomorfologiya, kalamushlar.

ПАТОМОРФОЛОГИЯ ВНУТРЕННИХ ОРГАНОВ ПРИ ЭКСПЕРИМЕНТАЛЬНОМ ИНТЕРСТИЦИАЛЬНОМ ПОРАЖЕНИИ ЛЁГКИХ ПРИ КОМБИНИРОВАННОМ ЛЕЧЕНИИ

Сабирова Р.А., Турсунов Д.Х., Турсунов Х.З., Рахманов А.Х.

Ташкентский государственный медицинский университет

В статье представлены результаты изучения морфологических изменений внутренних органов при экспериментальном интерстициальном поражении легких у крыс на фоне комбинированного лечения (экдистен, ацетилцистеин, полиоксидоний). Полученные данные показали выраженное снижение степени воспаления и деструктивных изменений в лёгких, печени и почках. Комбинированная терапия способствовала восстановлению нормальной структуры тканей и уменьшению признаков оксидативного стресса и гипоксического повреждения. Результаты подтверждают высокую эффективность фармакологической коррекции при интерстициальном поражении легких и перспективность дальнейших исследований.

Ключевые слова: интерстициальное поражение легких, комбинированное лечение, экдистен, полиоксидоний, ацетилцистеин, патоморфология, крысы.